

# The effect of ulipristal acetate treatment on symptomatic uterine fibroids within 12-months follow-up

Śławomir Woźniak, Piotr Szkodziak, Piotr Czuczwar, Ewa Woźniakowska, Maciej Paszkowski, Paweł Milart, Tomasz Paszkowski

III Chair and Department of Gynaecology, Medical University in Lublin

## Abstract

**Aim of the study:** The purpose of the study was to monitor the effect of ulipristal acetate treatment on symptomatic uterine fibroids within 12-months follow-up.

**Material and methods:** Fifty six patients with symptomatic uterine fibroids qualified for surgical treatment were included in the prospective observational study. All patients received preoperative oral UPA treatment for 3 months (1 × 5 mg). Patients that refused surgical treatment after UPA therapy were followed-up for the next 9 months. The volume of the intramural fibroid was estimated by TV-US using and integrated VOCAL 3D imaging program at baseline, after 3 months of UPA treatment and further at 3-months intervals.

**Results:** Before UPA mean dominant fibroid volume was estimated to be 216.0 cm<sup>3</sup> (38.4-768.2 cm<sup>3</sup>) and decreased to 117.6 cm<sup>3</sup> (12.6-668.0 cm<sup>3</sup>) after 3 months of UPA therapy. Mean percentage volume reduction was 45.6%. Mean hemoglobin level increased from an initial 10.1 g/dL (6.8-12.9 g/dL) to 12.6 g/dL (10.1-14.8) after 3 months of UPA therapy. At 12 months after initiating UPA treatment mean dominant fibroid volume decreased by 43.9%. In one third of followed-up patients the effect of 3 month UPA therapy persisted for the next 9 months.

**Conclusions:** Three month UPA therapy decreases fibroid volume and improves hemoglobin level before planned surgical treatment. In one third of followed-up patients the effect of 3 month UPA therapy persisted for the next 9 months.

**Key words:** ulipristal acetate, uterine fibroids, ultrasound.

## Introduction

Uterine fibroids are common benign tumours of the uterus. They are monoclonal tumours arising from uterine smooth muscle cells. Uterine fibroids contain large aggregations of extracellular matrix which is composed of collagen, fibronectin and proteoglycans. Fibroids are surrounded by a thin capsule made of connective fibrous tissue whose strands form a web-like structure. The condition affects one-fourth of women of childbearing age. In 20-50% of patients uterine fibroids are symptomless [1-4].

The main symptoms include excessively heavy menstrual bleeding, abnormal uterine bleeding between periods and compression symptoms. The latter are prone to cause pelvic pain, problems with urine passage and constipation [1,5].

In the mid-1990s first reports on the efficacy of GnRH analogue treatment introduced prior to scheduled surgical removal of uterine fibroids were published [6,7]. In 2012, a new drug, ulipristal acetate (UPA), started to

be marketed in Europe after being approved for the pre-operative treatment of symptomatic uterine fibroids in women of reproductive age. In January 2014, the approval was expanded to allow the possibility of one repeated course of a three-month treatment.

## Aim of the study

The aim of the prospective study was to assess the effects of ulipristal acetate (UPA) treatment on symptomatic uterine fibroids during a clinical follow-up period of 12 months.

## Material and methods

The study enrolled a total of fifty six patients aged 29-47 years old, with symptomatic uterine fibroids, qualified for surgical treatment. Prior to their scheduled surgery, all the patients received oral therapy with ulipristal acetate at a dose of 1 × 5 mg, starting on the first day

Corresponding author:

Tomasz Paszkowski, III Chair and Department of Gynaecology, Medical University in Lublin, ul. Jaczewskiego 8, Lublin, Poland, e-mail: tomasz.paszowski@am.lublin.pl

Submitted: 20.12.2013

Accepted: 03.02.2014

of menstruation and continuing over a three-month period. An ultrasound evaluation of the pelvic organs was performed in all the participants of the study at baseline and 13 weeks after the commencement of therapy. The volume of the dominant fibroid was calculated with VOCAL 3D technique (*Virtual Organ Computer-aided Analysis*). Patients who refused surgery after pharmacological treatment were followed up over the next 9 months after the completion of ulipristal acetate therapy, with clinical and ultrasound assessments performed at three months' intervals (Fig. 1).

**Results**

The mean volume of the dominant fibroid prior to introducing ulipristal acetate treatment was 216.0 cm<sup>3</sup> (38.4-768.2 cm<sup>3</sup>) and decreased to 117.6 cm<sup>3</sup> (12.6-668.0 cm<sup>3</sup>) after a three-month treatment period. The mean decrease in volume was 45.6% (Fig. 2).

After three months of therapy, a complete cessation of menstrual bleeding was achieved in 43 out of the total number of treated patients (77%). Pain associated with fibroids persisted in just four patients (a 64% decrease). The mean haemoglobin concentration prior to introducing pharmacological treatment was 10.1 g/dL (6.8-12.9), and after 12 weeks of UPA therapy rose to 12.6 g/dL (10.1-14.8).

Twenty seven patients upheld their initial consent to surgical treatment which was performed within up

to four weeks from the completion of pharmacological therapy. Eighteen patients had myomectomy (seven hysteroscopies and 11 laparotomies), and nine participants underwent subtotal hysterectomy (Fig. 1).

Directly after three months of ulipristal acetate treatment three patients refused their consent to a surgical procedure and requested embolisation of uterine arteries. The dominant fibroids diagnosed in these patients had a large volume at baseline (median: 571.3 cm<sup>3</sup>). After pharmacological therapy the median was 525.0 cm<sup>3</sup>, which shows that these patients had a poor response to pharmacological treatment. The mean reduction in the volume of the dominant fibroid in this group of patients was below 10%.

Another 26 patients (46.4% of the total number) after completing their UPA treatment opted against a surgical procedure due to the fact that all the clinical symptoms of fibroids had disappeared. During the next three months of follow-up (i.e. six months from the initiation of therapy) abnormal uterine bleeding recurred in seven out of these patients, prompting them to have the previously recommended surgical treatment. The remaining 19 patients experienced no recurrence of baseline symptoms three months after completing therapy, which is why they upheld their decision not to undergo surgery. In this group, the mean volume of fibroids determined three months after completing UPA treatment was 92.4 cm<sup>3</sup> (12.5-356.2 cm<sup>3</sup>), which represents a 46.2% decrease compared to the baseline value

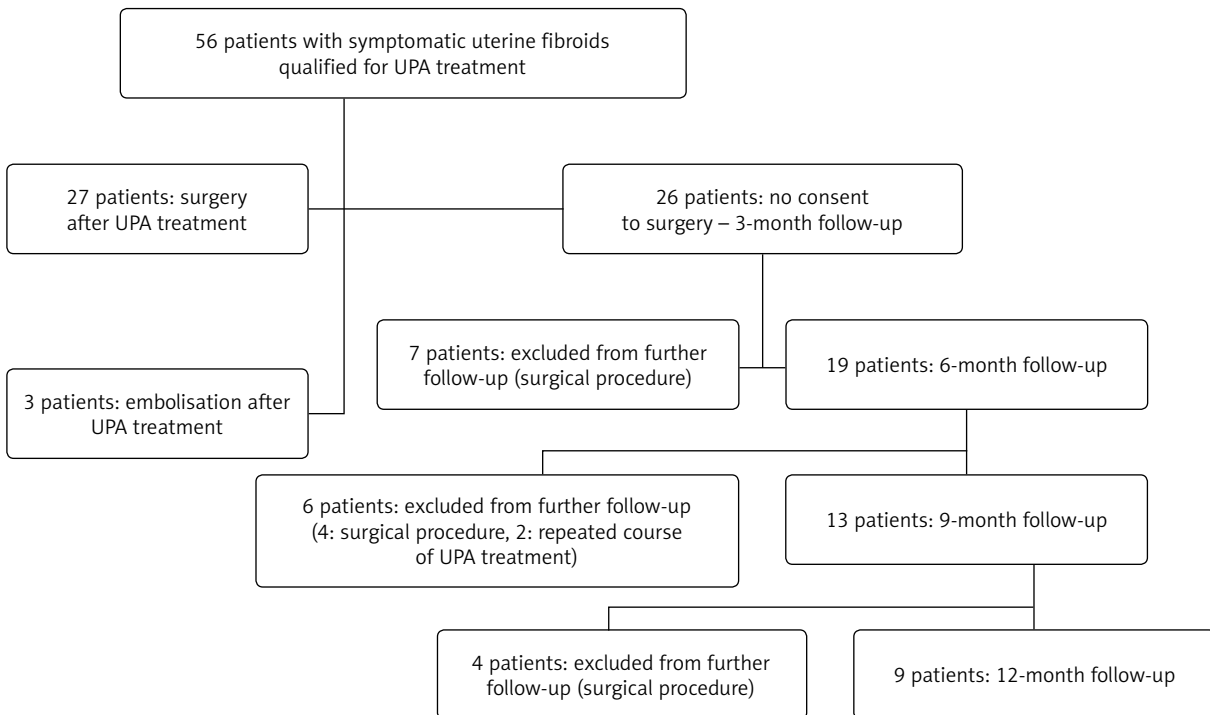
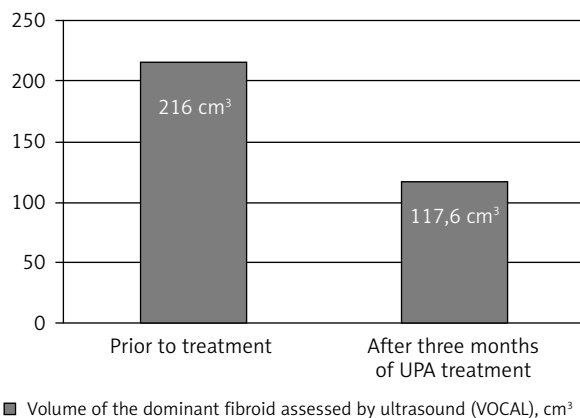
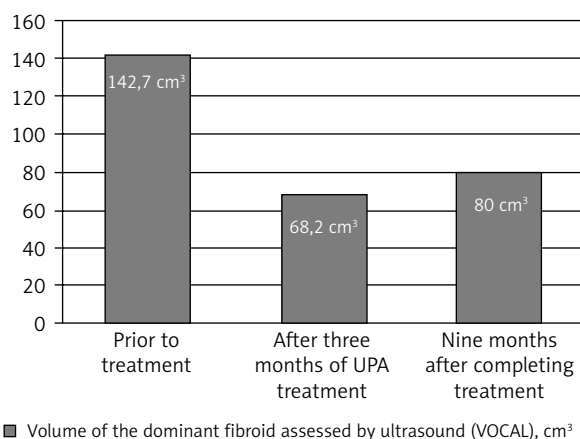


Fig. 1. Study design



**Fig. 2.** Size of the dominant fibroid prior to treatment and after a three-month therapy with ulipristal acetate (UPA) (n = 56)



**Fig. 3.** Change in fibroid size after UPA treatment within 12-months follow-up (n = 9)

of 171.6 cm<sup>3</sup> (50.7-482.8 cm<sup>3</sup>) that was noted in this group of patients before starting UPA therapy.

During the subsequent clinical assessment performed after another three-month period (i.e. nine months from the initiation of therapy and six months from its completion) nine women still reported no clinical symptoms, and the mean volume of the dominant fibroid determined in this group had not changed significantly since the previous examination. In another four women, the mean volume of the dominant fibroid was found to have increased since the last examination, however the fibroids were still symptomless, which is why the patients refused consent to surgery. In six patients heavy uterine bleeding returned during the period between three and six months after the completion of UPA treatment, which was accompanied by an increase in the volume of the dominant fibroid. As two of these patients still gave no consent to surgical treatment, they were offered a repeated course of ulipristal acetate treatment, to which they consented. The other four patients from this group decided to undergo surgery.

After another three months (i.e. 12 months from the initiation of therapy and 9 months from its completion) four patients opted for surgery due to the recurrence of clinical symptoms and increase in fibroid volume. The remaining nine women received further clinical and ultrasound follow-up. Nine months after the completion of UPA therapy the mean volume of the dominant fibroid in this group was 80 cm<sup>3</sup> (12.7-189.3 cm<sup>3</sup>), which represented an average reduction of 43.9% relative to the baseline value, accompanied by a slight increase (by an average of 14.7%) of the dominant fibroid volume between the third and sixth month after the completion of UPA treatment (Fig. 3).

### Discussion

A key role in the development of uterine fibroids is assigned to the stimulation of oestrogen receptors. Over the past several years, however, there have been multiple reports on the effects of treatment targeting the progesterone receptor which emphasize the importance of progesterone in the pathogenesis of these tumours. Several experimental studies have investigated mifepristone, an antagonist of the progesterone receptor, in doses from 5 to 50 mg for a period from three to six months, demonstrating its efficacy in reducing tumour weight and symptoms caused by fibroids [8]. The efficacy of using a selective progesterone receptor modulator (SPRM) in the form of ulipristal acetate with the aim of reducing the volume of uterine fibroids and relieving symptoms associated with the condition has been shown in a number of clinical trials with highly reliable results [9-11]. Clinical benefits of UPA therapy introduced before scheduled surgery include correction of patients' anaemia, reduction of intraoperative blood loss, facilitation of myomectomy instead of hysterectomy, laparoscopy instead of laparotomy and one-step hysteroscopic myomectomy [12].

Our study presents the follow-up of 56 patients who were treated for 84 days with ulipristal acetate at a single daily oral dose of 5 mg. The assessment performed at 13 weeks after the start of treatment revealed that the mean reduction in the volume of the dominant fibroid determined by 3D-VOCAL technique was 45.6%. In the PEARL I study, Donnez *et al.* found an approx. 21% reduction in volume, as assessed by MRI, after three months of UPA treatment [9]. In the PEARL II study, which involved 2D ultrasound measurements of the three largest uterine fibroids, the mean reduction of fibroid volume after three months of UPA treatment was 36% [10]. The mechanism of fibroid volume reduction induced by UPA can be ascribed to the proapoptotic and antiproliferative activity of the selective progesterone receptor modulator [13].

Following three months of UPA therapy, we observed the cessation of menstrual periods in 77% of study par-

ticipants. The haemoglobin concentration rose from the baseline level of 10.1 mg% to 12.6 mg% in week 13 of the follow-up. Donez *et al.* observed *amenorrhoea* in 73% of study patients after three months of ulipristal acetate treatment at a daily dose of 5 mg [10]. SPRM have a direct impact on the endometrium by maintaining a low level of proliferation of endometrial glands and stroma, and thus inducing *amenorrhoea* [13].

In the PEARL study, a total of 45% of patients decided not to undergo surgery after 12 weeks of UPA treatment. In our study, 46.4% of patients withdrew their consent to surgical treatment immediately after UPA therapy. These patients were followed up in the present study for nine months after completing UPA pharmacotherapy. After that follow-up period, nine women who were still satisfied with the outcome of pharmacological treatment refused consent to surgery (Fig. 1). Therefore satisfactory therapeutic effect achieved in a three-month UPA treatment was sustained for additional nine months after the completion of therapy in every third patient. In the opinion of our patients, the main factor determining their decision to either consent or refuse consent to surgical treatment after ulipristal acetate treatment was not the dynamics of changes in the size of fibroids but rather the presence and severity of symptoms accompanying fibroids impacting the perception of their quality of life.

## Disclosure

Authors report no conflicts of interest.

## References

1. Buttram VC Jr, Reiter RC. Uterine leiomyomata: etiology, symptomatology, and management. *Fertil Steril* 1981; 36: 433-445.
2. Naredi N, Bhattacharyya TK. Uterine Artery Embolization: A Nonsurgical Cure for Fibroids. *J S Asian Fed Obstet Gynecol* 2009; 1: 13-18.
3. Sabry M, Al-Hendy A. Medical treatment of uterine leiomyoma. *Reprod Sci* 2012; 19: 339-353.
4. Sabry M, Al-Hendy A. Innovative oral treatments of uterine leiomyoma. *Obstet Gynecol Int* 2012; 2012: 943635.
5. Stovall DW. Clinical symptomatology of uterine leiomyomas. *Clin Obstet Gynecol* 2001; 44: 364-371.
6. Donnez J, Nisolle M, Grandjean P, et al. The place of GnRH agonists in the treatment of endometriosis and fibroids by advanced endoscopic techniques. *BJOG* 1992; 99: 31-33.
7. Stovall TG, Summit RL Jr, Washburn SA, et al. Gonadotropin releasing hormone agonist use before hysterectomy. *Am J Obstet Gynecol* 1994; 170: 1744-1751.
8. Chabbert-Buffet N, Meduri G, Bouchard P, et al. Selective progesterone receptor modulators and progesterone antagonists: mechanisms of action and clinical applications. *Hum Reprod Update* 2005; 11: 293-307.
9. Donnez J, Tatarchuk TF, Bouchard P, et al. for the PEARL I Study Group. Ulipristal acetate versus placebo for fibroid treatment before surgery. *N Engl J Med* 2012; 366: 409-420.
10. Donnez J, Tomaszewski J, Vázquez F, et al. for the PEARL II Study Group. Ulipristal acetate versus leuprolide acetate for uterine fibroids. *N Engl J Med* 2012; 366: 421-432.
11. Bouchard P, Chabbert-Buffet N, Fauser B. Selective progesterone receptor modulators in reproductive medicine: pharmacology, clinical efficacy and safety. *Fertil Steril* 2011; 96: 1175-1189.
12. Woźniak S, Paszkowski T. Skuteczność leczenia mięśniaków macicy octanem uliprystalu w obserwacji dłuższej niż 3 miesiące. Analiza przypadków w ginekologii i położnictwie. PZWL, Warszawa 2013.
13. Horak P, Mara M, Dunder P, et al. Effect of a selective progesterone receptor modulator on induction of apoptosis in uterine fibroids in vivo. *Int J Endocrinol* 2012; 2012: 436174.